

# Radio frequency ablation (Rafaelo® procedure) for the treatment of prolapsing stage III° haemorrhoids- technique and initial results

## Background and objective

Haemorrhoids are a frequent proctological disease and occur in various forms with typical symptoms such as itching, pain, bleeding and weeping. Operative treatment is preferred in higher stages (III—IV°), whereas the stages (I—II°) that are less advanced successfully use strategies that regulate bowel movements as well as local, ambulatory treatments such as sclerotherapy and elastic ligation.

In the event of operative treatment in Germany, resectioning procedures, such as excision according to Milligan-Morgan or even the stapled hemorrhoidopexy, are preferred. These procedures generally require the use of anaesthesia, in-patient stay; furthermore the patient may experience post-operative pain in varying degrees, which may require pain therapy and may not be able to work for approximately 1-2 weeks. However, even non-resectioning procedures such as the haemorrhoidal arterial ligation, possibly in combination with a mucopexy, are often linked to relevant post-operative pain.

In the last few years, the so-called laser haemorrhoidoplasty was introduced by a few users in search of a less painful, safe and effective treatment of the advanced stages of haemorrhoids. This procedure is also initiated under anaesthesia and under in-patient conditions.

However, this method with different types of lasers, requires submucosal access via an external skin incision.

In this paper, we are first describing the application of a newly developed probe that is operated with radio frequency (co-called Rafaelo®: “radio frequency of haemorrhoids in local anaesthesia”, by F Care Systems, Antwerp, Belgium). A probe was used that was directly inserted into the haemorrhoid via a surgical proctoscope. The patients were mainly treated with local anaesthesia and were in a continuous outpatient setting. The goal of this paper was to examine the safety and effectiveness of the Rafaelo®

method in patients with segmental stage III° haemorrhoids.

## Study design and test methods

All patients with symptomatic stage III° haemorrhoids were included in the treatment. The following patient groups were excluded: Patients with circular anal prolapse and stage IV° haemorrhoids, pregnant or breastfeeding patients or patients with a pace maker, patients taking blood-thinning medications (excluding aspirin 100 1 x 1), hypercoagulopathy, patients with a history of rectal/anal carcinoma.

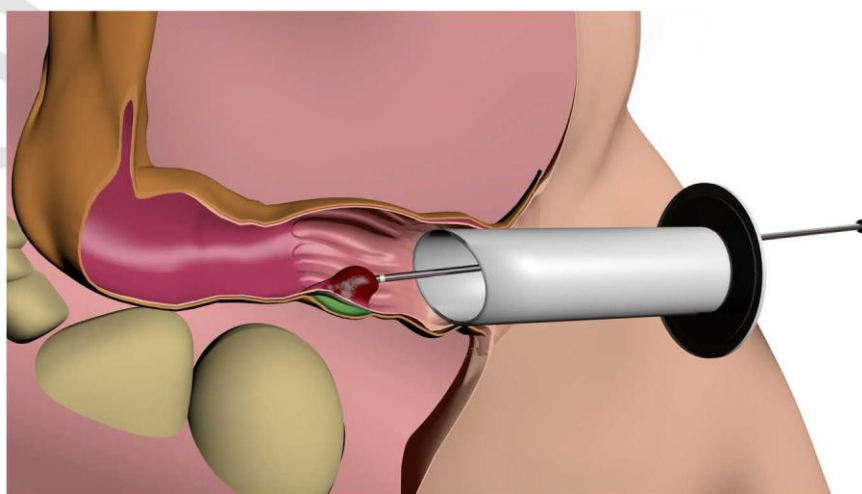


Fig. 1 Schematic representation of the Rafaelo® procedure. (Courtesy of F Care Systems)

**Tab. 1** Patient characteristics

Number of patients	102
Average age	49.9 (24-83) years old
Gender	91 male; 11 female
Pretreatment	46% none, 44% ligature/sclerotherapy, 2 x operation, 6 x RFA
Anaesthesia	80% local anaesthesia, 20% sedation + local anaesthesia
Number of haemorrhoidal knots treated per patient	60 patients/2 haemorrhoids 42 patients/1 haemorrhoid
Average time of the energy application	2:01 min

**Tab. 2** Intra and postinterventional complications

Complication	Number of patients	Type of complication
Serious complications	1 (1%)	Bleeding - operative revision without bleeding localisation
	1 (1%)	Chronic wound healing disorder/ Pain - Milligan-Morgan operation
Minor complications	2 (2%)	Intraoperative bleeding with suture
	4 (4%)	Anal venous thrombosis
	3 (3%)	Bleedings
	2 (2%)	Pain
	3 (3%)	Fever/chills

Prior to the intervention, the standard patient data (age, gender, pre-treatment, medication intake, pre-existing conditions) was gathered from all patients using the proctological symptom scale (PSS) [7].

The patients were either awake when treated in the lithotomy position or sedated with propofol. The side view proctoscope was inserted into the anal canal and 3-6 ml 1% lidocaine solution was injected between the submucosa and the inner muscle layer. The disposable RF probe (HPR45i, by F Care Systems) was presented proximally to the dentate line up to the upper pole of the haemorrhoid in the haemorrhoidal tissue (Fig. 1). In order to achieve the greatest distance between the muscle layers, the tip of the probe was aligned intraluminally. Now the RFA was applied in a total of 4 positions, first in the proximal and then the distal proportion of the haemorrhoid. A total of up to 2500 J were applied per haemorrhoidal segment with a maximum temperature development of 125-130 °C.

During the intervention, the alert patient gave feedback on any strong temperature increases noticed in the rectum. In this case, the procedure was aborted and the tissue was briefly cooled down using a cold and wet compress.

If the haemorrhoidal tissue turned considerably white, the whole probe was removed and the insertion channel was separately coagulated. A few RF spots were administered with the probe tip on the surface of the haemorrhoid in order to achieve a scarred shrinkage of the mucosa. Finally, possible bleedings were looked for, which, if necessary, were touched by the probe tip and staunching by means of ablation. Then a final cooling of the treatment area was carried out using a damp, cold compress for approx. 30 seconds. The patient was then able to leave the practice. If a sedation was performed, the patient was discharged after the recovering phase.

Ibuprofen 400 mg (max. 1200 mg, alternative: paracetamol 500 mg) was prescribed for pain therapy. A first postinterventional visit by the doctor took place between the 3rd and 7th day following intervention.

A questionnaire regarding any pain that occurred, the intake of pain medication and the inability to work was carried out. Furthermore, the patient underwent an anal inspection and a rectal-digital examination.

Further tests took place after 4 weeks and 6 months. This is when a proctological examination (including proctoscopy) was carried out and PSS was gathered.

The statistical evaluation of the results took place by means of averages, standard deviations and percentages.

## Results

During the period of March 2015 and February 2018, a total of 102 patients (12 % female, 88 % male) were treated by two surgeons (Tab. 1). So far, 95 patients were re-examined after 4 weeks and 70 patients after 6 months. The average age was 49.9 years (24-83 years). 46% of the patients were firstly treated for haemorrhoids, and haemorrhoidal sclerotherapy and/or ligature treatment was preceded in 44% of the patients. The medical history of two patients indicated a previous haemorrhoidal operation; in 6 patients a further knot was treated in another localisation after previous RFA treatment. None of the patients underwent an additional proctological intervention during the same session.

A total of 80 % of the patients were treated under local anaesthesia, whereas 20% personally decided to be sedated for the treatment (generally with propofol). One haemorrhoid was treated in 42 patients and 2 haemorrhoids were treated in one session among 60 patients. On average 1877J were applied per haemorrhoid. The average duration of the radio frequency application amounted to 2 minutes, the whole operation usually lasted between 10 and 15 minutes. A suture ligature had to be performed intraoperatively on two occasions due to severe bleeding from the insertion channel (Tab. 2).

## Radiofrequency ablation for prolapsing stage 3 hemorrhoids (Rafaelo® procedure)—technique and first clinical results

### Abstract

**Background.** Patient with prolapsing stage III hemorrhoids usually undergo surgery. Here, anesthesia and a hospital stay are mandatory and accompanied by painkiller intake in line with the inability to work. In this study, we applied radiofrequency therapy (Rafaelo®, F Care Systems, Antwerp, Belgium) for outpatients under local anesthesia with a minimally invasive treatment procedure. **Objective.** The safety and efficacy of the Rafaelo® procedure for prolapsed stage III hemorrhoids were investigated.

**Material and methods.** The newly developed radiofrequency probe was applied in patients with stage III hemorrhoids. All procedures were carried out with the patient under local anesthesia or local anesthesia plus sedation

in an outpatient setting. The proctological Symptom score (PSS) was assessed preoperatively, 4 weeks, and 6 months after the treatment, to evaluate bleeding, pain, itching, and weeping. Furthermore, pain intensity (visual analogue scale, VAS) and painkiller intake were documented.

**Results.** In a 3-year period, 102 patients with stage III hemorrhoids underwent surgery. The total PSS preoperatively was 9.9, and postoperatively 1.8 after 4 weeks and 1.1 after 3 months. The mean VAS score was 3.2. Of the patients 32% did not report any pain, 61% did not take painkillers and 16% took painkillers for 1 day. Of the patients one with a bleeding episode underwent rectoscopy in an operating theater; however, the bleeding

source could not be verified and one patient was subjected to hemorrhoid excision due to an ulcerative wound. Other complications, such as thrombosed external hemorrhoids ( $n = 4$ ), bleeding ( $n = 3$ ), fever ( $n = 3$ ), and pain ( $n = 2$ ) could be resolved under conservative treatment. **Discussion.** The Rafaelo® procedure is safe and effective treatment for prolapsing stage III hemorrhoids. This method is suitable for use in the outpatient sector and is only slightly restricting for patients.

### Keywords

Hemorrhoids • Radiofrequency • Ablation • Prolapse • Minimally invasive

3 patients had smaller bleedings postoperatively; this did not require an intervention. One patient was examined in an external hospital due to a secondary bleeding. A site of bleeding was not found intra-operatively.

Over the course of treatment, 4 other patients developed anal venous thrombosis, which were treated conservatively with an ointment. On three occasions, patients reported very severe pain, which subsided after two sessions of pain therapy.

One patient developed a chronic pain syndrome in the area of the treated haemorrhoid. Finally, an excision according to Milligan-Morgan resulted in a recovery. Three patients reported temporary temperature increases/shivers after the operation but this did not require subsequent treatment.

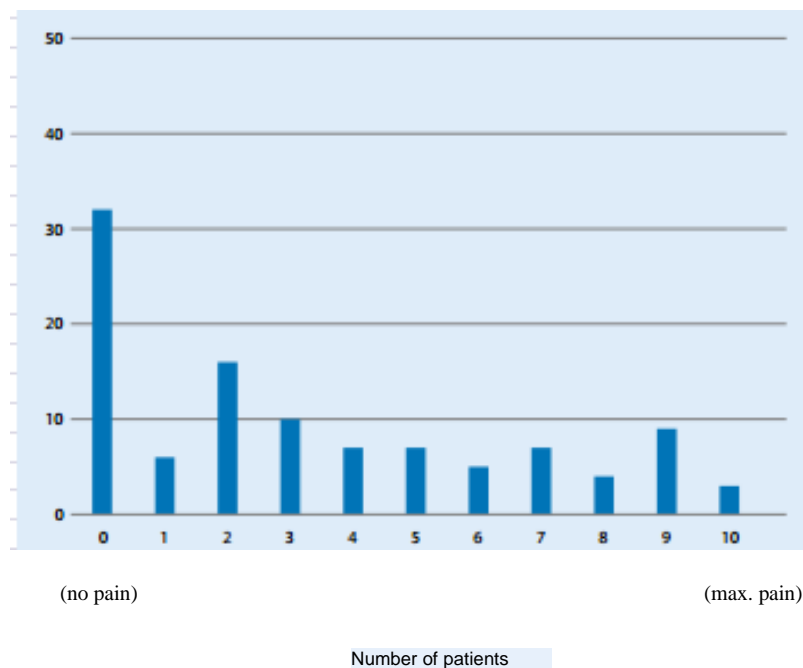


Fig . 2 Maximum postinterventional pain on the visual analogue scale (VAS)

2 haemorrhoidal knots were treated (60 patients) and in 11 cases it resulted in post-operative complications, whereas the treatment of a single haemorrhoidal knot resulted in complications in 6 patients.

The specification of maximum pain in the first week (3-7 days) according to the VAS score showed that 32% of the patients had no pain. The average VAS score was 3.2% (Fig. 2).

The documentation of the postinterventional pain medication requirement showed that 62 patients did not take any pain killers. 16 other patients took pain killers for just one day. As mentioned above, one patient developed chronic pain syndrome (□ Fig. 3).

In the case of all symptoms (itching, pain, bleeding, weeping) in the PSS, it had resulted in a significant drop and/or complete freedom of the symptoms that were described pre-operatively (□ Fig. 4) both 4 weeks as well as 6 months after the treatment.

An operative treatment was necessary in one case due to recurrent, prolapsing haemorrhoids (stapled hemorrhoidopexy).

All other patients did not need to be treated again due to being free of symptoms and no repeated RFA treatments were carried out.

Most of the patients did not receive a sick note (89%) and were able to continue their work or did not experience any restrictions as a result of the procedure (84% of the patients).

### Discussion

This is the first description with a single probe for radio frequency ablation for prolapsing haemorrhoids. At a Polish centre, the featured probe was used with 2500 patients in a total of 4000 interventions over a course of 4 years (not published yet). This did not result in any serious complications. Long-term results are not known.

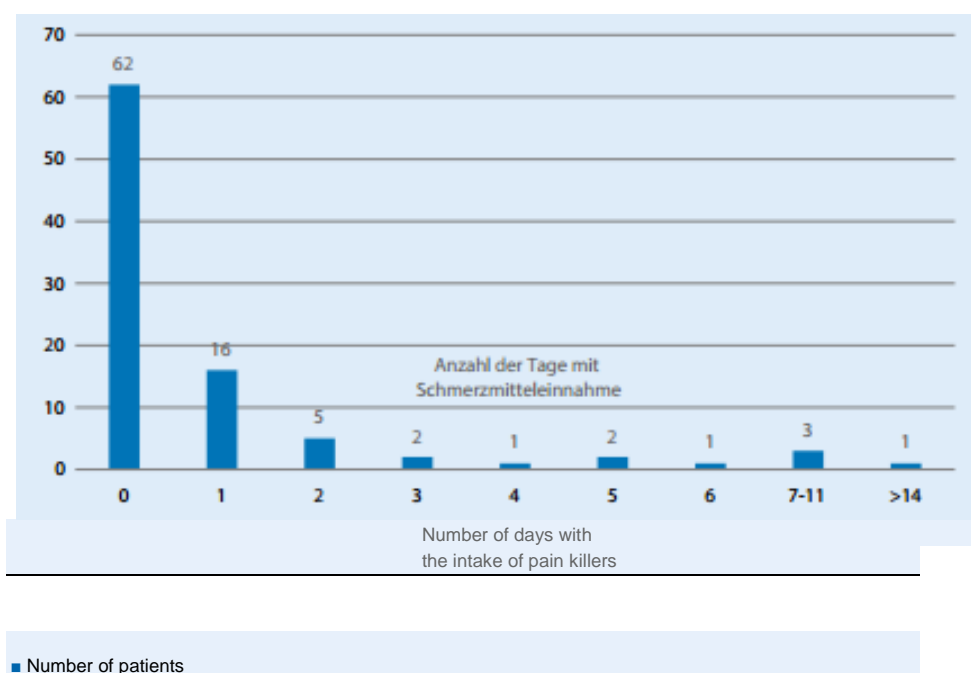
The goal of this study was to evaluate the effectiveness of the Rafaelo® treatment performed for stage III haemorrhoids in an outpatient setting.

The radio frequency application resulted in a coagulation of the haemorrhoidal tissue. A necrosis developed next to the oedema in the first week following the operation and finally resulted in fibrosis with scarring of the wound.

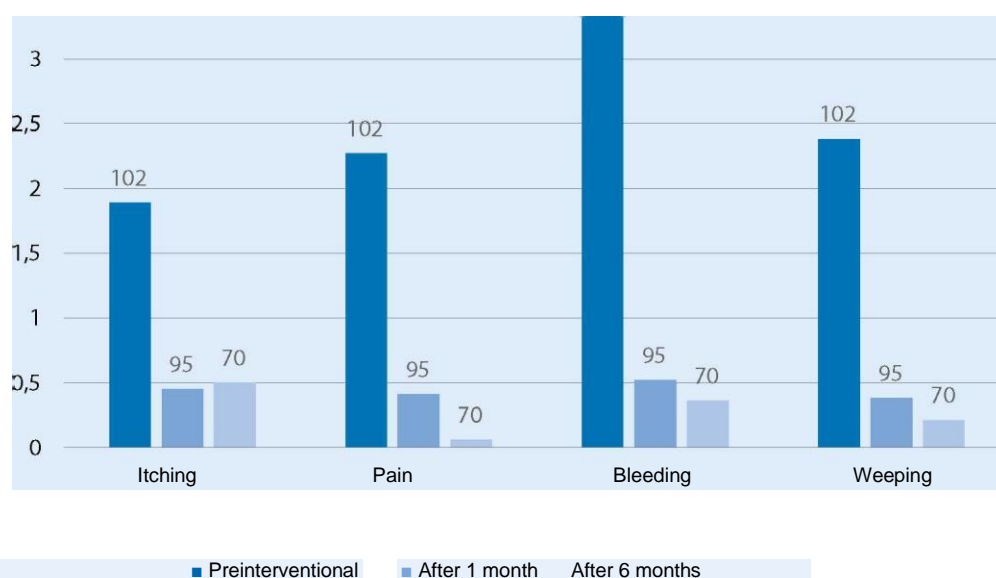
The scarring also brought about a tightening of the tissue with a removal of the haemorrhoidal prolapse.

The underlying muscles are effectively protected during the operation by a fluid cushion (lidocaine 1%) that is injected in advance. In our patient population it did not result in any rectal wall necrosis or abscess. The insertion point had to be sutured twice during the operation. Both patients had minimal blood loss and continued with outpatient care. However, this requires proctological expertise in order to safely master such situations. It is particularly important to treated the anal mucosa carefully during the RFA and it must not be destroyed by the heat. The personal learning curve of the technique described also includes the quantity of energy applied, which is dependent on the size of the haemorrhoid being treated, and is therefore, variable. This is where patient feedback regarding excessive heat development in the rectum is helpful as well as the white colouration of the haemorrhoids, which visually confirms that coagulation took place. Postinterventional complications such as anal venous thrombosis, smaller secondary bleedings, pain and temporary fever are typical problems viewed after haemorrhoidal operations. Our patients did not report any signs of incontinence. Only one patient reported chronic pain symptoms with a fissural wound healing disorder in the area of the RFA and this required a second intervention. All other complications healed without consequences.

The safety of the method was proven in a total of 102 patients (treatment of 162 haemorrhoidal knots) because it did not result in any other undesired incidents. After the intervention, all patients were discharged from outpatient treatment. Only a few patients reported restrictions as a result of the intervention and only every 10th patient needed a sick note. This is in sharp contrast to a study currently published in Japan, where conventional haemorrhoidectomies resulted in hospital stays of up to one week and the inability to work for up to 2 weeks [5].



**Fig. 3-4** Necessary pain medication following the intervention (Ibuprofen 400 mg up to 3x per day)



**Fig. 4-4** Proctological Symptom Score

After the intervention, two thirds of the patient left without any pain medication. The average, maximum VAS score of 3.2 is comparable with the data following laser haemorrhoidoplasty [6, 8, 9, 14].

The haemorrhoidal complaints that were expressed pre-operatively were significantly and statistically reduced by the intervention.

The PSS value achieved after 4 weeks and 6 months can be compared to the value of the normal population without proctological problems, as described by Kramer et al. [7].

One patient (0.71 %) had to be re-operated due to a recurrent prolapse with corresponding symptoms. This value is very low, however due to the short follow-up time it cannot be compared with the results found in the literature of other methods.

If anything, longer post-intervention periods would result in a valid statement on the rate of recurrence.

Existing radio frequency therapy applications mainly concerned liver surgery interventions, particularly in the case of local therapy of the hepatocellular carcinoma and metastatic liver disease.

Similar to the technique presented here, a probe is inserted directly into the tumour and this brings about thermal destruction. The advantages described compared to conventional surgical resection include fewer complication rates, with higher rates of recurrence [13]. The radio frequency therapy application is also used for the ablation of Barrett's mucosa in the oesophagus, inter alia with the 360° balloon probe. This also reports a lower complication rate of the procedure with good healing of the dysplastic mucosa [12].

Radio frequency application is widely used in the treatment of varicose changes in the leg veins. In a current review, the superiority of RFA compared to laser therapy regarding post-operative complications with the same effectiveness and safety was discussed on the basis of the present studies [4].

A radio frequency application in proctological surgery known as the haemorrhoidal excision is performed with the Ligasure system or the harmonic scalpel. These methods technically correspond to the excision haemorrhoidectomy according to Milligan-Morgan. In a systematic review, both surgical methods were assessed with a relatively high post-operative complication rate but a low risk of recurrent prolapse [11]. In a meta analysis evaluating the Ligasure haemorrhoidectomy compared to conventional haemorrhoidectomy, a majority of the studies found that the Ligasure technique was more beneficial with regard to post-operative pain (VAS score) and convalescence or going back to work [10].

Current studies with selective radio frequency application on the haemorrhoids using a ball probe was first presented by Gupta et al. in the early 2000s. However, the anal mucosa was destroyed in the process. To ensure the results, the RDA was combined with a haemorrhoidal ligature. In several publications the author has reported good post-operative results with low complication rates and low post-operative pain. Long-term results are not specified [2, 3].

The impact the haemorrhoidal ligature has on the results presented is still unclear.

Compared to the previously applied radio frequency techniques in haemorrhoidal treatment, the Rafaelo® procedure brings about a selected thermodestruction of the haemorrhoidal tissue without damaging the surrounding tissue. Experiments made it possible to prove a maximum expansion of thermal destruction of 1 cm above the catheter tip in ex vivo vein surgery [1]. This results in a minimal impairment of the patient during and after the procedure.

Furthermore, there were no external, post-operative wounds, which is linked to a high level of comfort for the patient.

To date, this resulted in a low rate of post-operative problems among our patients with very good healing and symptom control of the haemorrhoids.

Overall this study made it possible to prove patient safety, which means that it did not result in any serious adverse effects or misuses. The application area consisted of stage III° haemorrhoids, whereby a maximum of 2 knots were treated in a single session. This approach was selected in order to minimise postinterventional pain and secondary bleeding - similar to ligature treatment. The use of the probe following a previous Longo operation was excluded in order to avoid a thermal destruction of the anastomosis area.

Further studies are to provide information on the frequency of recurrence in the long-term. Prospective randomised studies are preferable compared to excision haemorrhoidectomy.

### Summary for practice

**The Rafaelo® procedure for stage III haemorrhoidal treatment deals with a minimally invasive technique with low post-operative pain development and very short recovery periods for the patients. Users should only be active, experienced, coloproctological surgeons.**

**Long-term results and comparative studies are still missing.**

### Correspondence address



**PDDr.med.H. Schäfer**  
Praxis für  
Enddarmkrankungen und  
Endoskopie, Pan Klinik  
Zeppelinstr. 1, 50667  
Cologne, Germany nc-  
schaeffa39@netcologne.de

### Compliance with ethical guidelines

Conflict of interests. H. Schäfer, S. Tolksdorf and C Vivaldi received travel expenses from F Care Systems within the framework of attending conferences.

All described examinations performed on people were done so with the consent of the respective ethics commission in accordance with national law as well as in accordance with the Declaration of Helsinki dated 1975 (in the current, revised version). A declaration of consent was received from all patients that were involved!

Open Access - This article was published under the Creative Commons name 4.0 International Licence (<http://creativecommons.org/licenses/by/4.0/deed.de>), which enables the use, copy, processing, distribution, and reproduction in any medium and format, provided you formally state the original author(s) and the source, add a link for Creative Commons Licences and state whether any changes were carried out.

## Bibliography

1. Czuprin C, Brunnert A, Jost D, Palmer C, Hupp T (2014) Wärmeausdehnung und Schrumpfung der VSM unter Anwendung der endovenösen Radiofrequenz (EVRF) und Kontrolle durch das endoskopisch videoassistierte Crosseclipping (EVCC) und der offenen Crossektomie. 55. Jahrestagung der Deutschen Gesellschaft für Phlebologie, Hamburg
2. Gupta PJ, Heda PS, Kalaskar S (2009) Randomized controlled study between suture ligation and radio wave ablation and suture ligation of grade III symptomatic hemorrhoidal disease. *Int J Colorectal Dis* 24:455-460
3. Gupta PJ, Kalaskar S (2009) Radiowave ablation and mucopexy for prolapsing hemorrhoids - a pilot study. *Int J Surg* 7:223-227
4. He G, Zheng C, Yu MA et al (2017) Comparison of ultrasound-guided endovenous laser ablation and radiofrequency for the varicose veins treatment: An updated meta-analysis. *Int J Surg* 39:267-275
5. Iida Y, Saito H, Takashima Y et al (2017) Procedure for prolapsed hemorrhoids (PPH) with low rectal anastomosis using a PPH 03 Stapler: low rate of recurrence and postoperative complications. *Int J Colorectal Dis* 24:455-460.
6. Jahanshahi A, Mashhadizadeh E, Sarmast MH (2012) Diode laser treatment of symptomatic hemorrhoid: a short term clinical result of a mini invasive treatment, and one year follow up. *Pol Przegl Chir* 84:329-332
7. Kraemer M, Kara D, Rzepisko M et al (2015) A simple tool to evaluate common disorders: Validation of a "proctological Symptom scale". *Int J Colorectal Dis* 30:679-682
8. Maloku H, Gashi Z, Lazovic R et al (2014) Laser hemorrhoidoplasty procedure vs open surgical hemorrhoidectomy: a trial comparing 2 treatments for hemorrhoids of third and fourth degree. *Acta Inform Med* 22:365-367
9. Naderan M, Shoar S, Nazari M et al (2017) A randomized controlled trial comparing laser intra-hemorrhoidal coagulation and milligan-morgan hemorrhoidectomy. *J Invest Surg* 30:325-331
10. Nienhuijs SW, De Hingh IH (2010) Pain after conventional versus Ligasure haemorrhoidectomy. A meta-analysis. *Int J Surg* 8:269-273
11. Simillis C, Thoukididou SN, Slesser AA et al (2015) Systematic review and network meta-analysis comparing clinical outcomes and effectiveness of surgical treatments for haemorrhoids. *Br J Surg* 102:1603-1618
12. Van Vilsteren LG, Bergman JJ (2010) Endoscopic therapy using radiofrequency ablation for esophageal dysplasia and carcinoma in Barrett's esophagus. *Gastrointest Endosc Clin N Am* 20:55-74
13. Weis S, Lranke A, Mossner J et al (2013) Radiofrequency (thermal) ablation versus no intervention or other interventions for hepatocellular carcinoma. *Cochrane Database Syst Rev*. <https://doi.org/10.1002/14651858.CD003046.pub3>
14. Weyand G, Theis CS, Lofana AN et al (2017) Laser hemorrhoidoplasty with 1470 nm diode laser in the treatment of second to fourth degree hemorrhoidal disease - a cohort study with 497 patients. *Zentralbl Chir*.